

Continuing education
Credit Hours Awarded: 2 hours

MAKING PRELIMINARY ADAPTATION OF TEMPORARY CROWNS

General Instructions

According to the Board rule, training programs **MUST** consist of all of the following:

1. An initial assessment to determine the base entry level of all participants in the program. At a minimum, participants must be currently certified by the Dental Assisting National Board or must have two years of clinical dental assisting experience;
2. A didactic component;
3. A laboratory component, if necessary;
4. A clinical component, which may be obtained under the personal supervision of the participant's supervising dentist while the participant is concurrently enrolled in the training program; and
5. A postcourse competency assessment at the conclusion of the training program.

Conduct an **initial assessment** to determine base entry level level of all participants in the program.

Didactic

Required Reading

Finkbeiner & Johnson, Comprehensive Dental Assisting: A Clinical Approach, published by Mosby, ISBN number is 0-8151-3239-5, p. 803-808.

Suggested references to supplement didactic component:

Phinney, Donna J., Halstead, Judy H.: *Delmar's Handbook of Assisting*, p. 408-411.

Strupp, William; 2370 Sunset Pt. Rd., Clearwater, Fl. 33675-1423

Gordon Christensen tape, "Simple Temporary Restorations."

Burns, David R., DMD, Beck, David A., DDS, and Steven K. Nelson, DMD, "A review of selected dental literature on contemporary provisional fixed prosthodontic treatment: Report of the committee on Research in Fixed Prosthodontics of the Academy of Fixed Prosthodontics, "The Journal of Prosthetic Dentistry, Vol. 90, Number 5, pages 474-497.

Objectives

1. Select functions of temporary (provisional) restorations.
2. Indicate features of a sound provisional restoration.
3. List the categories of provisional materials.
4. Describe the steps involved in fabricating, adapting and removing acrylic temporary crowns/bridges.
5. Describe the steps involved in adapting, placing and removing a preformed metal temporary crown.
6. State postoperative instructions that are given to a patient that has a temporary crown/bridge.
7. Relate safety measures for the patient and operator during the process of making preliminary adaptation of temporary crowns/bridges.

MAKING PRELIMINARY ADAPTATION OF TEMPORARY CROWNS

Didactic:

- I. Background
 - A. Provisionalization Overview
 - B. Features of a Sound Provisional Restoration
 - 1. Proximal Contacts
 - 2. Occlusal Contacts
 - 3. Smooth Polish
 - 4. Proper Emergence Profile
 - 5. Adequate Marginal Seal

- II. Material Overview
 - A. Prefabricated Crowns
 - B. Chemically-Cured Materials
 - 1. Acrylics
 - C. Preformed Metal Crowns
 - D. Modifying the Impression
 - E. Casting the Temporary Restoration

Background

Provisionalization Overview

Provisional restorations stabilize and protect tooth structure during the time span from final impression through the cementation of a final laboratory-fabricated prosthesis. "Temporary" and "provisional" are terms that are synonymous in dentistry. Crown and bridge procedures tend to put a high degree of stress on tooth structure due to the removal of enamel and the exposure of dentinal tubules. A provisional restoration must protect traumatized tooth structure from the rigors of the oral environment until a more permanent restoration is placed without harming the gingiva.

Provisional restorations must provide adequate pulp protection, thermal insulation, marginal integrity, soft tissue compatibility, patient function, space maintenance and adequate esthetics. Generally, a provisional crown or bridge is fabricated by a dentist or dental auxiliary and cemented in place using a temporary crown and bridge cement. However, dental laboratories are becoming increasingly involved in the fabrication process for long-term temporization procedures such as implants and long-span bridges.

Features of a Sound Provisional Restoration

Proximal Contacts

A provisional crown or bridge should exhibit good contact with adjacent tooth structure. This will help prevent tooth migration, maintain interproximal tissue health, and keep the proper space maintenance for a final laboratory fabricated crown or bridge (see Figure 1).

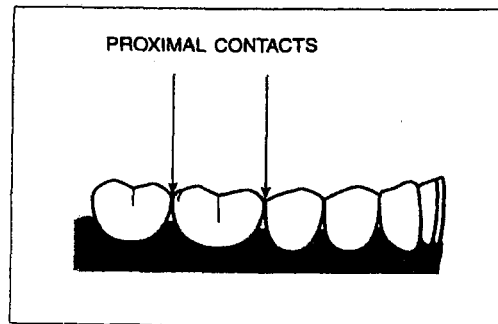


Figure 1.
Proximal Contacts
of Natural Tooth
Structure

Occlusal Contacts

A provisional restoration must maintain good occlusion and occlusal contact with the opposing dentition. Providing proper occlusal contact keeps opposing teeth from supra-erupting (see Figure 2).

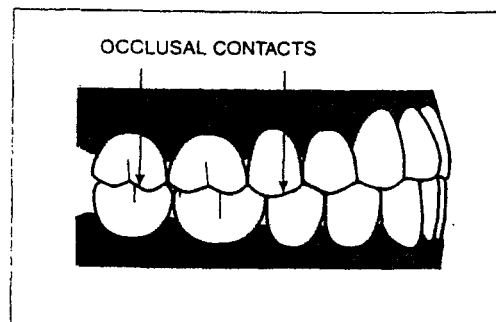


Figure 2.
Occlusal Contacts
of Natural Tooth
Structure

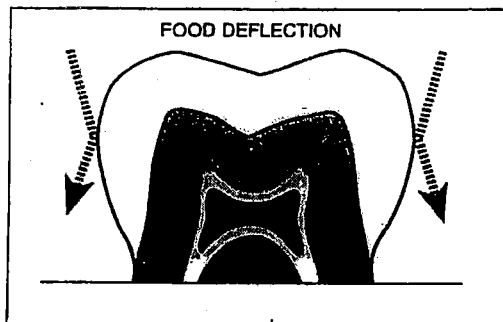
Smooth Polish

Provisional restorations need a reasonably smooth surface finish in order to promote good gingival health. The final surface of a temporary crown or bridge must be somewhat resistant to plaque build-up and non-irritating to gingival tissue.

Proper Emergence Profile

The natural shape of tooth structure has many advantages. The proper emergence profile of a tooth deflects food away from the gingival tissue so that natural soft tissues are not harmed by mastication (see Figure 3). A provisional restoration must provide adequate function for its duration in a patient's mouth.

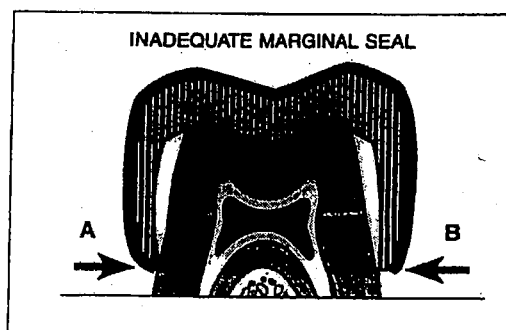
Figure 3.
Proper Emergence
Profile



Adequate Marginal Seal

A sound margin between natural tooth structure and any type of restoration is important for many reasons. Eliminating microleakage, minimal plaque retention and promotion of gingival healing are a few of the most important benefits of a good marginal fit. Provisional restorations that are over-contoured (A), or overhang the finish line of the preparation (B), can lead to plaque build-up and consequently, gingival recession. (see Figure 4).

Figure 4.
Poor Marginal
Contour



Material Overview

Provisional materials are generally classified into two distinct categories. They are prefabricated and chemically-cured materials. Prefabricated materials such as 3M Iso-Form™ crowns have become popular over the years because of ease-of-use and time savings. Chemical systems are used widely due to versatility, custom fit and esthetics.

Prefabricated Crowns

Prefabricated crowns are available in many forms for a variety of single-unit applications. Since 1975, 3M has been the market leader in prefabricated crowns. Their use has a broad application base from short-term to long-term coverage. Prefabricated temporary crowns are manufactured for the following uses: 3M Iso-Form crowns or 3M gold-anodized crowns for adult molar coverage, and 3M polycarbonate crowns for adult anterior use.

Prefabricated crowns are a viable method of single-unit provisionalization with benefits that include ease of use and significant time savings over chemical alternatives.

Chemically-Cured Materials

Chemically-cured systems are generally classified into two distinct categories including acrylics and resins. Within each of these groups there is a further distinction between self-cured, multi-phase and light-cured materials.

Acrylics

Acrylic materials have been used for provisional restorations since the late 1930's for both single- and multiple-unit temporary restorations. The appeal of acrylic materials has been their low cost, esthetics and versatility. Acrylic materials are the most commonly used material, on a per unit basis, by both dentists and dental schools in the global market.

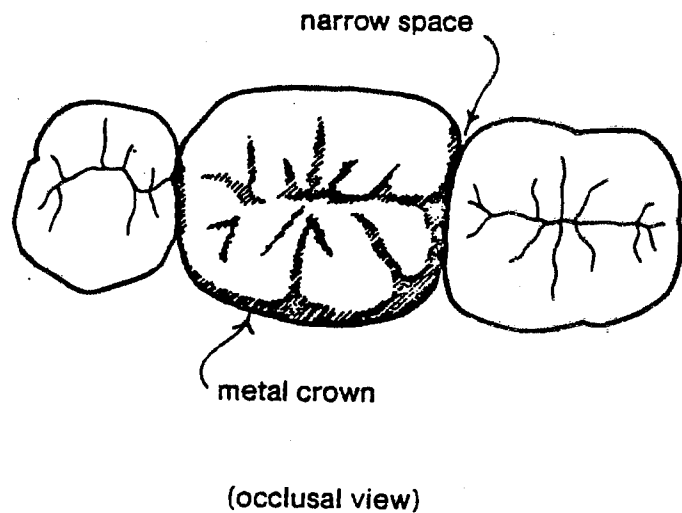
Acrylic materials, although versatile and inexpensive, have several undesirable characteristics. Acrylic materials are prepared by mixing a polymeric powder and liquid (monomer) until a honey-like consistency is reached. This takes approximately 30-45 seconds. Acrylics exhibit a strong and objectionable odor to both patients and dental staff. Acrylic materials also give off significant heat during their exothermic setting reaction which could cause pulpal damage if not carefully controlled. In addition, acrylic undergoes significant shrinkage.

Two basic types of acrylic materials with minor variations are sold in today's market. They are polymethyl methacrylate and poly-R' methacrylates. The R' represents either an ethyl, vinyl or an isobutyl functional methacrylate system.

PREFORMED METAL CROWNS

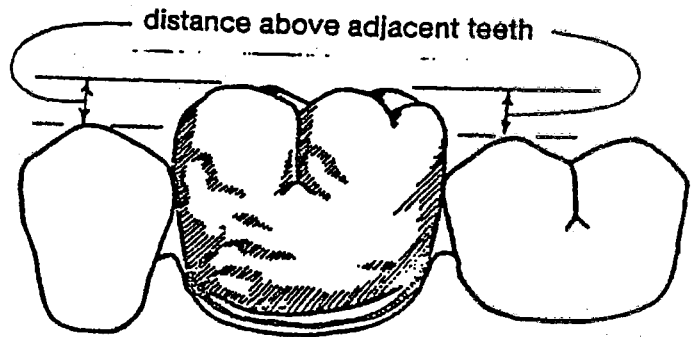
Metal crowns come in several sizes. Try to find one just small enough to fit snugly between the adjacent teeth and yet large enough to slip over the neck of the prepared tooth and rest on the shoulder of the preparation.

The metal is soft and pliable, so if a crown is too narrow in one direction and too wide in another, you can usually bend it with your fingers to fit the neck of the tooth. You can also bend the crown slightly to make it fit between the adjacent teeth, but don't bend the contact area flat like this:

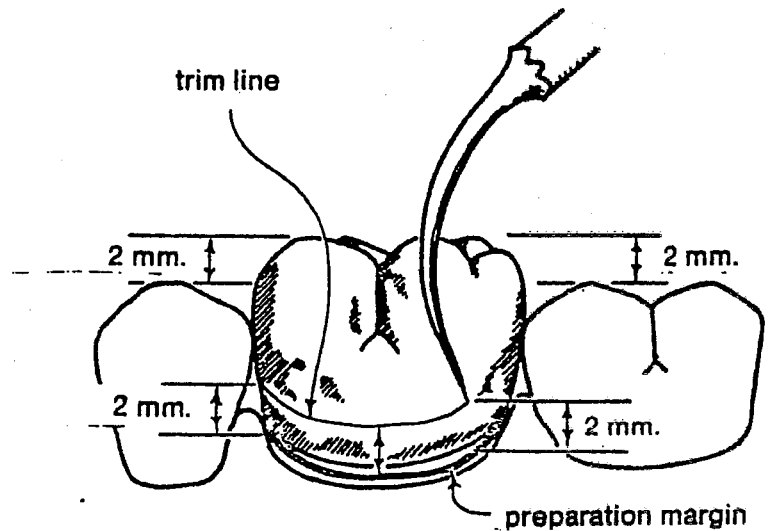


The narrow space will trap food and be hard to clean. The situation diagrammed above calls

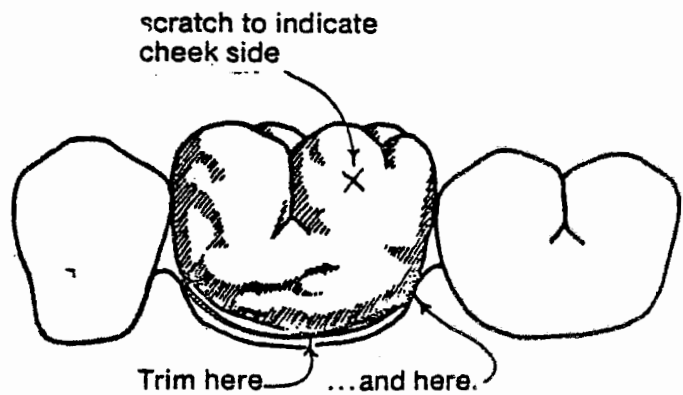
Slip the crown down onto the shoulder of the preparation, and then estimate how much farther it will need to go to be level with the adjacent teeth:




Use an explorer to trace a trim line into the soft metal of the crown:

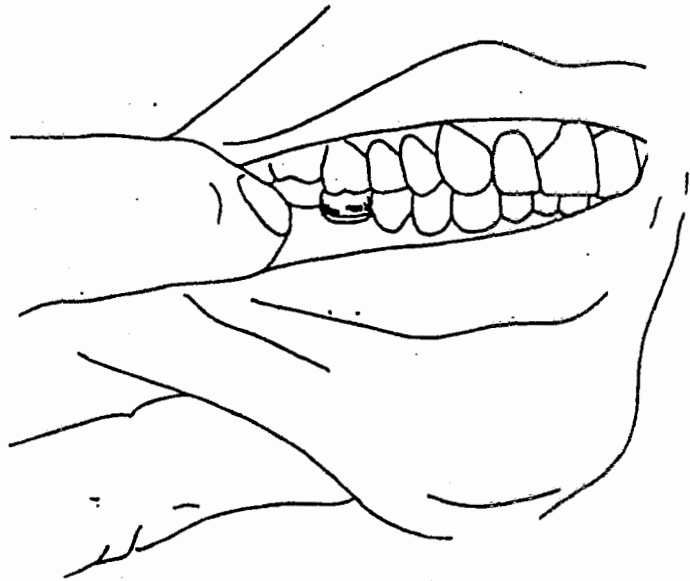


Replace the crown. (Don't get it on backwards. It helps to make a mark on the cheek side with the explorer.) See if the trimmed edge matches the margin of the preparation. You'll probably need to trim off a bit here and there to get a good fit:



If the edges of the crown are loose, crimp them in with a pliers like this:



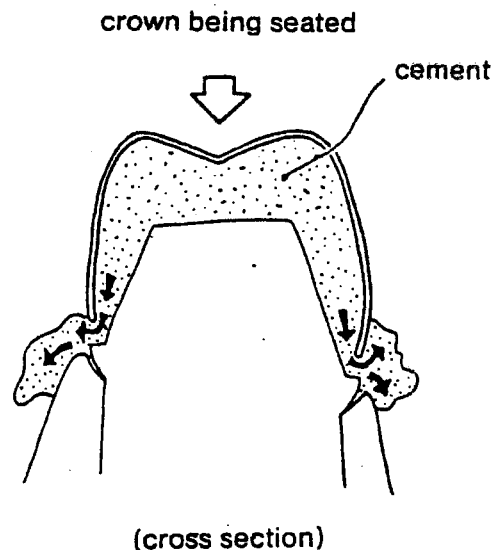


If the crown looks so high that the patient couldn't close all the way without forcing the crown down past the margin of the preparation, you'll have to trim some more off. If the crown is just a little too high, then have the patient bite down gently while you observe.

If you have the crown trimmed just right, the patient can bring the adjacent teeth into contact without displacing the crown, and the opposing tooth will make it perfect by slightly denting the soft metal crown.

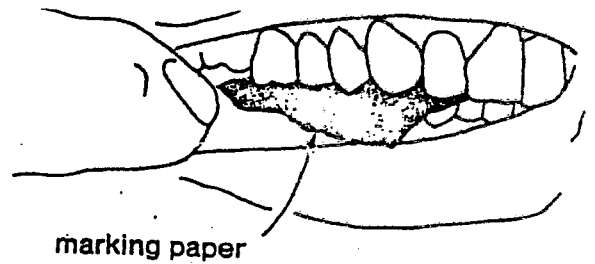
Remove the crown and dry it on the inside with an air syringe. Also air dry the prepared tooth.

Fill the crown about half full with temporary cement. There must be enough cement so that an excess will be forced out at the margin as you seat the crown:

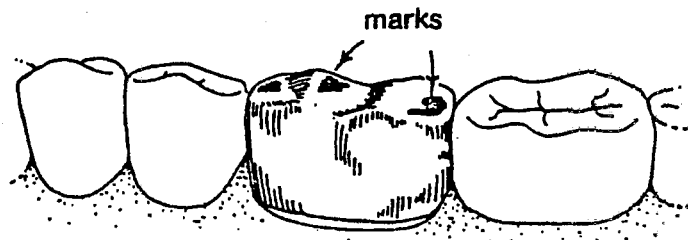


Place the crown on the tooth and have the patient close firmly to seat it. If the patient says he can't close completely because the crown is too high, check to see that the crown is in the correct position. Most types of cement harden in about one minute, so you should still be able to move it to the correct position.

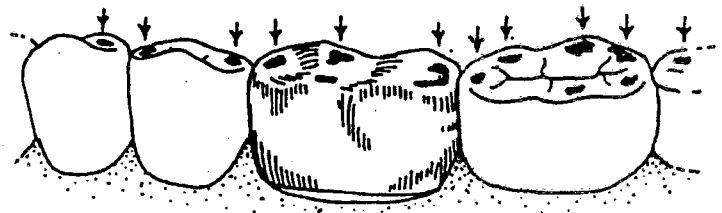
Wait for the cement to harden, and then



Examine the teeth. The blue marks left by the paper indicate points of contact with opposing teeth:

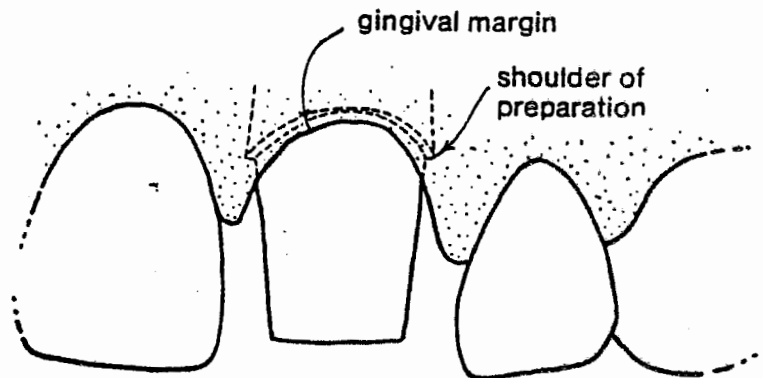


In the drawing above, spots from the marking paper appear only on the temporary crown. In other words, the temporary crown is too high. The solution is to reduce the marked areas of the temporary crown with a bur. Then test the occlusion again with the paper. Keep reducing the dark spots and retesting until the temporary crown and the adjacent teeth show the same amount of blue markings, like this:




If you have the opposite problem, that is, if the marks appear only on the adjacent teeth, you'll have to start over again with a new metal crown and a bit less trimming. DO NOT try to adjust the occlusion by reducing the adjacent

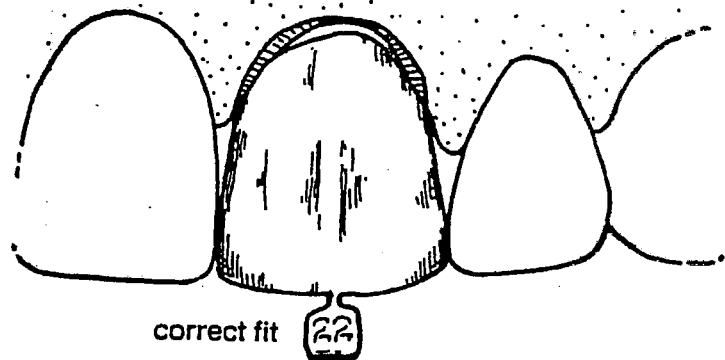
When full crowns are placed on anterior teeth, the preparation is usually carved so that the margin or shoulder is hidden underneath the gingiva like this:



We're going to simplify the illustrations here, however, by showing the shoulder just at the level of the gingival margin where you can see it:




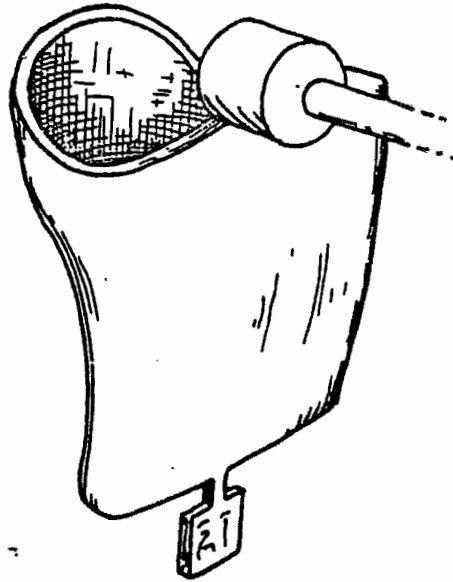
Select a crown that's just wide enough for a snug fit between the adjacent teeth:



Notice that the edge of the crown pictured above doesn't fit the margin of the preparation exactly. With precast acrylic crowns, you don't need the close fit required with precast metal crowns. (You'll see why in a minute.) So you can usually find an acrylic crown that fits without any trimming.

In some cases, however, in order to get a crown wide enough for the space, you'll have to use one that's too long like this:




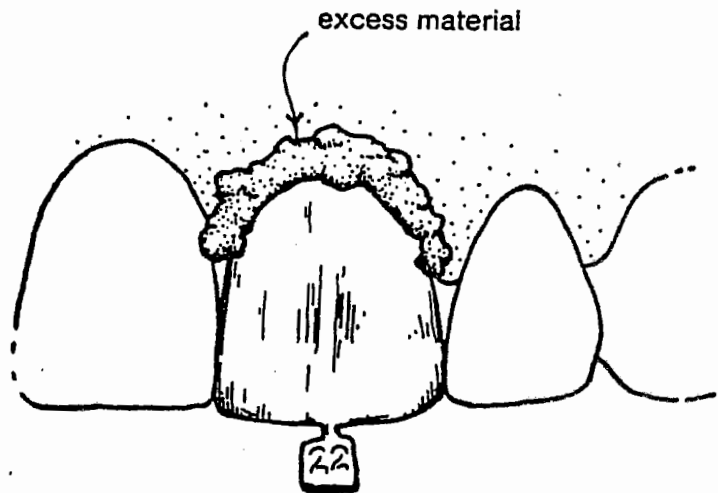


If you can't find a crown that's just the right width, use a bur to reduce one that's a little too wide.

When you have a crown that's the correct width and length, remove it and air dry the inside surface.

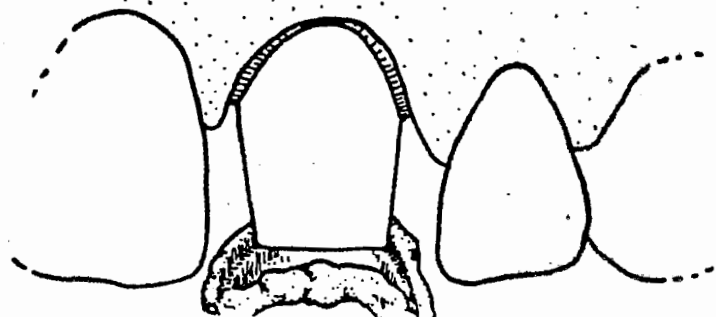
Mix a small amount of fast-set acrylic material and fill the precast crown with it:



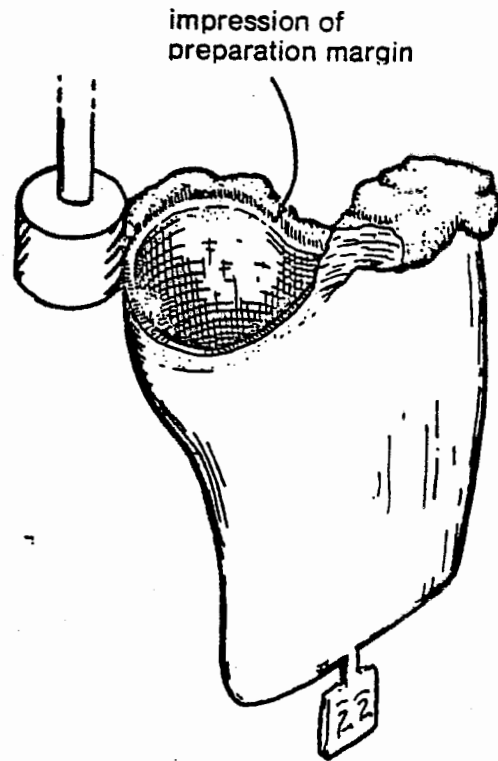


Pick up a small piece of the mixed material and warm it in your hand. It will set at about the same rate as the material being moulded around the warm tooth inside the precast crown.

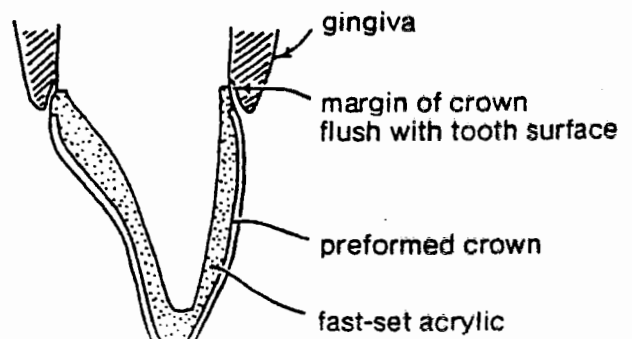
The mixed acrylic will adhere to the dry inside surface of the acrylic crown rather than to the wet tooth. So when the material in your hand becomes firm, but still resilient, you can remove the whole temporary crown:



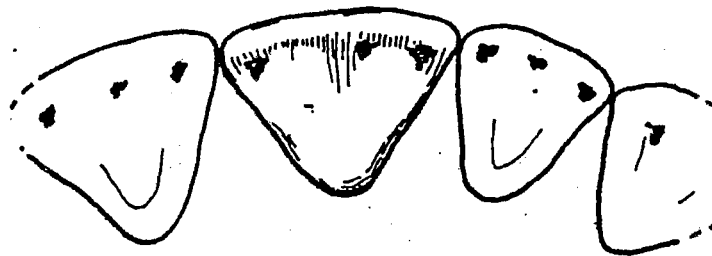
tooth surface below the preparation margin:



Be careful not to remove too much acrylic material. Try to achieve a normal tooth contour so that the gingiva is adequately protected



adjust the occlusion so that the temporary crown shares the occlusal load with the adjacent teeth. As with precast metal crowns, use marking paper to locate the highspots, and reduce them with a bur until marks appear on the adjacent teeth:

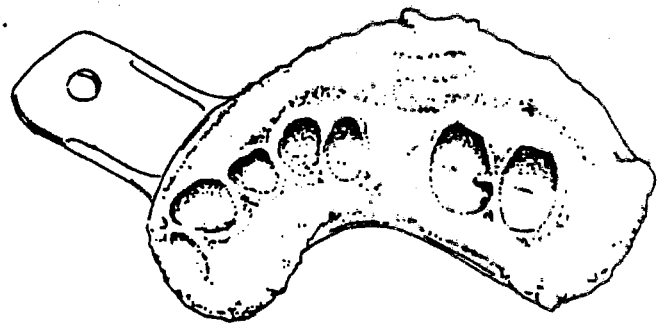


Remove the crown and polish the outside surfaces so that they will be smooth to tongue and lips and won't become a source of irritation.

Finally, air dry both the prepared tooth and the inside of the crown. Place a thin film of cement inside the crown and seat it firmly on the dry tooth. Wipe off any excess cement that oozes out at the margin.

ations which include several adjacent teeth or a bridge across an edentulous area. Instead of using precast acrylic crowns or preshaped metal crowns, the entire temporary restoration is made with fast-set acrylic material. The acrylic material is cast in an alginate impression of the area to be restored, which enables all or part of the temporary restoration to assume the original shape of the teeth, that is, their shape before preparations have been carved on them. For that reason, you must take the alginate impression of the area to be restored first, and preserve it in a moist towel while the preparations are being carved.

You can use a half-arch impression for this technique provided you include in the impression not only the area to be restored, but also the teeth adjacent to the ones to be prepared. The impression shown below includes an edentulous area to be fitted with a bridge.

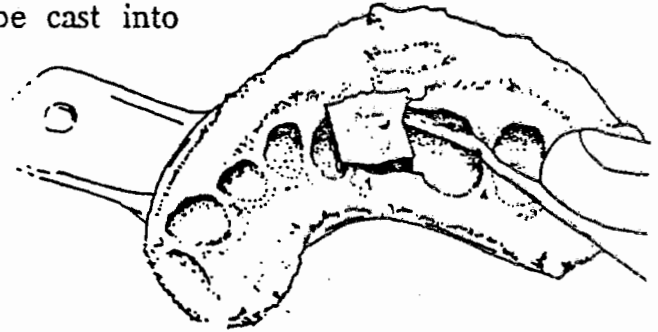


Modifying the Impression

There's no sense reproducing defects in a temporary restoration. Notice, for instance, that the above impression shows the presence of a cavity on the distal of the first molar. To avoid reproducing such a defect, use a wax spatula to carve it out of the alginate impression.



carve out the block of alginate material representing the edentulous area so that a bridge between the existing teeth will be cast into the temporary restoration:



If you are restoring two or more adjacent crowns, cut out the alginate representing the contact areas so that the acrylic temporary crowns will be joined together in the casting for extra strength.



Remember to keep the impression moist while you're waiting for the preparation carving to be completed.

Casting the Temporary Restoration

When you have modified the impression to account for defects and missing teeth, and when the preparation carving has been completed, mix the fast-set acrylic material and load the impression with it. Place material in parts of the impression which represent the prepared teeth or bridges, but not in the spaces for adjacent teeth:



MAKING PRELIMINARY ADAPTATION OF TEMPORARY CROWNS

Clinical/Lab

Go back to **I-II** and perform each of these procedures in a clinical setting and a lab, if appropriate. Please note that all clinical training must be done under the personal supervision of a dentist, which means that the dentist must be physically present in the treatment room.

Postcourse competency assessment must be completed at the conclusion of the training program. This means you must develop a test to ensure participants have learned the necessary material and can perform these skills to written and clinical competency. Keep a copy of your competency assessment and the participants' results as part of the documentation of training.

Document successful completion of this training. You may use the Board's sample Documentation of Training Form and maintain this proof in the dental office of practice.